

**CASE REPORT**

# Primary Tuberculous Abscess of Vastus Lateralis Muscle

Shiraz M Bhatti, Jeewan S Prakash, Bobby John

**Abstract**

Skeletal muscle tuberculosis without underlying osseous or extra osseous involvement is an extremely rare presentation of tuberculosis. We present a case of isolated tubercular abscess of the vastus lateralis muscle without an evident primary focus in a 52 year old immunocompetent male. The diagnosis was confirmed by histological examination. The patient showed marked improvement with a standard four-drug regimen.

**Key Words**

Tuberculosis, Skeletal Muscle, Vastus Lateralis

**Introduction**

About 3% of patients with tuberculosis have musculoskeletal involvement, mostly spondylitis, osteomyelitis or arthritis. However, primary tuberculous involvement of skeletal muscle has rarely been described in the medical literature, and its manifestations may mimic malignant or other inflammatory diseases, leading to misdiagnosis (1). Most of these cases have been reported in patients in an immunocompromised state, having chronic illness or with underlying bone disease. We present a case of intramuscular tuberculosis of vastus lateralis muscle in an immunocompetent male without any primary source of infection.

**Case Report**

A 52 year old healthy male without any co-existing medical problems presented to the hospital with a painful mass in his left proximal thigh for 2 months. There was associated history of low grade evening rise of temperature. There was no associated respiratory complaint, weight loss or anorexia. Neither was there a history of trauma or an intra-muscular injection at the affected site or a history of close contact with tuberculosis. Examination revealed a firm to soft, ill-defined mass 10cm x 5 cm x 4cm in size in the lateral aspect of left proximal-thigh, well separated from the underlying bone. The skin over it appeared normal, mobile and with no sinuses (*Fig 1*). There was no limitation of motion of the ipsilateral hip or knee joint. The distal neurovascular status was normal. MRI scan showed a lobulated well defined mass involving the vastus lateralis muscle. The lesion displayed low signals on T1 and inhomogenously bright signals on T2 weighted images (*Fig 2*). Radiographs of the chest, ipsilateral femur and hip and knee joints were normal,

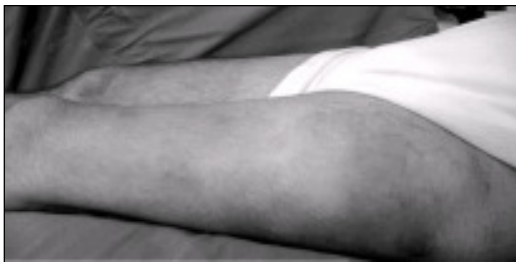ESR was elevated at 100, blood counts and renal parameters were within normal limits. A fine needle aspiration cytology (FNAC) of the mass revealed pleomorphic suggestive of neoplastic pathology. Patient was operated with a probable diagnosis of a soft tissue sarcoma. At surgery, a 10 cm x 7cm x 5cm mass was found within the vastus lateralis. The mass was adherent to overlying tensor fascia lata, lobulated and filled with caseous material. The mass was excised with a thin rim of muscle around and sent for biopsy. Histopathological examination revealed presence of caseating granulomatous inflammation tissue consistent with tuberculosis. No atypical or malignant cells were seen. The patient was then started on a regimen of four-drug antitubercular chemotherapy (2HREZ/4HR3) and improved clinically with resolution of symptoms by three months. At the two-year follow-up, the patient had no signs of disease activity.

**Discussion**

Tuberculosis has staged a remarkable comeback today following HIV infected cases. Unusual presentations of tuberculosis are being increasingly diagnosed in both immunocompromised and immunocompetent hosts [2]. About one-fifth of diagnosed new cases of tuberculosis have an extrapulmonary lesion, of which about one-tenth involve the musculoskeletal system. Tuberculosis of soft tissue without underlying bony pathology is rare and the pathogenesis is still confusing (3). There are very few reports in the English literature of primary muscular tuberculosis without any involvement of bone or in immunocompetent patients (4-8). Petter (9) recorded only one case of primary muscular tuberculosis in over 6,000

From the Department of Orthopaedics, Christian Medical College & Hospital, Ludhiana-141008, Punjab, India

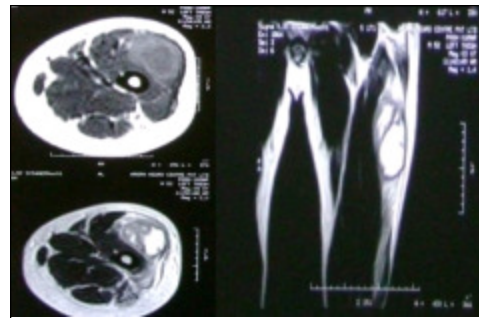
Correspondence to : Dr Shiraz M Bhatti, Associate Professor Department of Orthopaedics, CMC & Hospital, Ludhiana-141008, Punjab, India



**Fig1. Soft Tissue Swelling on the Proximal & lateral Aspect of Left Thigh**

cases of all types of tuberculosis, an incidence of 0.015 per cent. Hence, as such isolated primary skeletal tuberculosis without any associated involvement of the adjacent bone or viscera is considered only a diagnosis of exclusion over a soft tissue tumour or a pyogenic abscess. It is of interest to note that most of the reported cases have been described frequently in association with immunodeficient individuals as in HIV infected patients, renal failure patients, patients on chemotherapy or corticosteroid and chronic drug abusers (3,10,11). A few reports have indicated that primary tuberculosis in muscle may be transmitted by direct inoculation with contaminated needles and syringes (12).

Pathogenesis of skeletal muscle tuberculosis is still not understood well. Most of the authors believe the involvement of skeletal muscle to be secondary to underlying bones, bursae, synovial sheaths of nearby joints, by direct inoculation (trauma, syringe) or hematogenous dissemination but selective primary muscular involvement without osseous involvement is rare (13). The bursa around the ischial tuberosity and the greater trochanter bursa are the most common bursae to be affected by tuberculous bursitis which could subsequently lead to involvement of the muscles of the thigh (11). Our case is of interest because there were no associated co-morbid conditions and there was no involvement of underlying bone or the bursae as evident from the radiographs and MRI findings. The rarity of skeletal muscle tuberculosis has been variously attributed to high lactic acid content of muscles, absence of reticuloendothelial or lymphatic tissue, rich blood supply and the highly differentiated state of muscle tissue. However, none of these possibilities seem to be an adequate explanation (4). As seen in the present case, skeletal muscle tuberculosis usually has a slow clinical course and can be misdiagnosed as sarcoma, or perhaps a benign soft tissue tumour. Parasitic infections like cysticercosis or hydatid cyst, fungal infection, hematoma with secondary infection can present with similar soft tissue mass. High index of clinical suspicion is the key to diagnosis. Possibility of tuberculous abscess should be strongly considered in endemic areas. Blood parameters



**Fig 2. MRI Showing Well Lobulated Mass in Substance of Vastus Lateralis Muscle**

may not be indicative of any infectious pathology and raised erythrocyte sedimentation rate may be the only consistence finding (3). A normal chest radiograph, absence of systemic symptoms, or the absence of other foci of active tuberculosis should not dissuade one from making the diagnosis. MRI scan of the involved muscle can be very helpful in differential diagnosis. Prognosis is usually good with appropriate antitubercular therapy and surgical intervention.

#### References

1. Wang JY, Lee LN, Hsueh PR, Shih JY, *et al.* Tuberculous myositis: a rare but existing clinical entity. *Rheumatology* 2003; 42: 836-40
2. Global tuberculosis control: surveillance, planning, financing. WHO report 2005. Geneva, World Health Organization(WHO/HTM/TB/2005.349)
3. Sen RK, Tripathy SK, Dhatt S, *et al.* Primary tuberculous pyomyositis of forearm muscles. *Indian J Tuberc* 2010; 57:34-40
4. Dhananjya S, Kumar V. Primary tuberculous abscess of rectus femoris muscle. A case report. *J Infect Dev Ctries* 2009; 3:476-78
5. Nuwal P, Dixit R. Tuberculosis of rectus abdominis muscle. *Indian J Chest Dis Allied Sci* 2007; 49: 239-240
6. Trikha V, Gupta V. Isolated tuberculous abscess in biceps brachii muscle of a young male. *J Infect* 2002; 44:265-66
7. Narasimhan R, Gayathri AR, Hegde SK. Tuberculous abscess of soleus muscle. A case report. *Lung India* 2005; 22:130-31
8. Abdelwahab IF, Keenan S. Tuberculous abscess of the brachialis and biceps brachii muscles without osseous involvement. A case report. *J Bone Joint Surg Am* 1998; 80:1521-24
9. Petter CK. Some thoughts on tuberculosis of fascia and muscle. *Lancet* 1937; 57:1156-19
10. Ergin F, Arslan H, Bilezikci B, *et al.* Primary tuberculosis in the gluteal muscle of a patient with chronic renal failure. A rare presentation. *Nephron* 2001; 89:463-66
11. Puttick MPE, Stein HB, Chan RMT, *et al.* Soft tissue tuberculosis : a series of 11 cases. *J Rheumatology* 1995; 22(7): 1321-25.
12. Heycock JB, Noble TC. Four Cases of Syringe-transmitted Tuberculosis. *Tubercle* 1961; 42:25-27
13. Derkash RS, Makley JT. Isolated tuberculosis of the triceps muscle. A case report. *J Bone Joint Surg Am* 1979; 61:948